

Screening of *CD96* and *ASXL1* in 11 Patients with Opitz C or Bohring-Opitz Syndromes

Roser Urreizti,¹ Neus Roca-Ayats,¹ Judith Trepát,¹ Francisco Garcia-Garcia,^{2,3} Alejandro Aleman,³ Daniela Orteschi,⁴ Giuseppe Marangi,⁴ Giovanni Neri,⁴ John M. Opitz,⁵ Joaquin Dopazo,^{2,3} Bru Cormand,¹ Lluïsa Vilageliu,¹ Susana Balcells,¹ and Daniel Grinberg^{1*}

¹Department of Genetics, Faculty of Biology, Universitat de Barcelona, CIBERER, IBUB, Barcelona, Spain

²Department of Computational Genomics, Centro Investigación Príncipe Felipe, Valencia, Spain

³BIER, CIBERER, Valencia, Spain

⁴Istituto Genetica Medica, Università Cattolica Sacro Cuore, Policlinico A Gemelli, Roma, Italy

⁵Pediatrics, University of Utah School of Medicine, Salt Lake City, Utah

Manuscript Received: 16 October 2014; Manuscript Accepted: 23 September 2015

Opitz C trigonocephaly (or Opitz C syndrome, OTCS) and Bohring-Opitz syndrome (BOS or C-like syndrome) are two rare genetic disorders with phenotypic overlap. The genetic causes of these diseases are not understood. However, two genes have been associated with OTCS or BOS with dominantly inherited *de novo* mutations. Whereas *CD96* has been related to OTCS (one case) and to BOS (one case), *ASXL1* has been related to BOS only (several cases). In this study we analyze *CD96* and *ASXL1* in a group of 11 affected individuals, including 2 sibs, 10 of them were diagnosed with OTCS, and one had a BOS phenotype. Exome sequences were available on six patients with OTCS and three parent pairs. Thus, we could analyze the *CD96* and *ASXL1* sequences in these patients bioinformatically. Sanger sequencing of all exons of *CD96* and *ASXL1* was carried out in the remaining patients. Detailed scrutiny of the sequences and assessment of variants allowed us to exclude putative pathogenic and private mutations in all but one of the patients. In this patient (with BOS) we identified a *de novo* mutation in *ASXL1* (c.2100dupT). By nature and location within the gene, this mutation resembles those previously described in other BOS patients and we conclude that it may be responsible for the condition. Our results indicate that in 10 of 11, the disease (OTCS or BOS) cannot be explained by small changes in *CD96* or *ASXL1*. However, the cohort is too small to make generalizations about the genetic etiology of these diseases.

© 2015 Wiley Periodicals, Inc.

Key words: Opitz C; trigonocephaly; Bohring-Opitz; *CD96*; *ASXL1*; whole exome sequencing; developmental disease; molecular diagnosis; rare disease

INTRODUCTION

Opitz C syndrome (OTCS, also known as the C trigonocephaly syndrome, MIM #211750) is a rare disorder of trigonocephaly and

How to Cite this Article:

Urreizti R, Roca-Ayats N, Trepát J, Garcia-Garcia F, Aleman A, Orteschi D, Marangi G, Neri G, Opitz JM, Dopazo J, Cormand B, Vilageliu L, Balcells S, Grinberg D. 2016. Screening of *CD96* and *ASXL1* in 11 patients with Opitz C or Bohring-Opitz syndromes.

Am J Med Genet Part A 170A:24–31.

associated hypertelorism, multiple buccal frenula, limb defects, wide alveolar ridges, visceral anomalies, redundant skin, hypotonia, psychomotor, and mental retardation. Less than 60 cases are known worldwide [Opitz et al., 2006].

Although the molecular basis of OTCS and its inheritance are unknown, this disorder was recently associated with mutations in the *CD96* gene (Cluster of Differentiation 96, also called *TACTILE* for “T cell activation increased late expression,” MIM *606037) [Kaname et al., 2007]. In an OTCS individual, these authors

Susana Balcells and Daniel Grinberg are Co-last authors.

Conflict of interest: None.

Grant sponsor: Associació Síndrome Opitz C, Terrassa, Spain; Grant sponsor: Spanish Ministerio de Ciencia e Innovación; Grant numbers: SAF2011-25431, SAF2014-56562-R, FECYT-PRECIPI-TA; Grant sponsor: Catalan Government; Grant numbers: 2009SGR971, 2014SGR932; Grant sponsor: CIBERER; Grant number: U720.

*Correspondence to:

Daniel Grinberg, Departament de Genètica, Facultat de Biologia, Universitat de Barcelona, Av. Diagonal 643, 08028 Barcelona, Spain.

E-mail: dgrinberg@ub.edu

Article first published online in Wiley Online Library (wileyonlinelibrary.com): 7 October 2015

DOI 10.1002/ajmg.a.37418

discovered a balanced chromosomal translocation, t(3;18), that disrupted the *CD96* gene at the 3q13.3 breakpoint. They also identified a missense mutation (c.839C > T, p.Thr280Met) in exon six of *CD96* in one BOS patient. The *CD96* gene encodes the CD96 antigen, a member of the immunoglobulin superfamily, which plays a role in cell adhesion [Fuchs et al., 2004]. Cells with mutated CD96 protein display loss of adhesion and growth activities in vitro [Kaname et al., 2007]. Moreover, the expression patterns of this gene, including bone and fetal brain are consistent with organs and tissues involved in the abnormalities of the C syndrome.

Recently, the role of *CD96* in OTCS was questioned by Darlow et al. [2013]. These authors found a disruption of the *CD96* gene in patients bearing a t(2;3) balanced translocation and who developed renal cell carcinoma without symptoms of OTCS. To reconcile both findings, it was proposed that the breakpoint region of chromosome 18 involved in the translocation found by Kaname et al. [2007] could bear the gene responsible for OTCS in that patient.

Regarding inheritance, some reports of affected sibs support autosomal recessive segregation [Antley et al., 1981; Opitz et al., 2006]. Likewise, normal karyotypes in most patients, unaffected parents with multi-affected offspring, an equal sex ratio of affected individuals, and consanguineous mating support autosomal recessive inheritance. However, many other patients are sporadic cases, which suggests the possibility of dominant inheritance or germ-line mosaicism [Sargent et al., 1985]. OTCS is highly variable, so that many symptoms that define OTCS overlap with Bohring–Opitz syndrome (BOS, MIM #605039). While some experts have defined these pathologies as two different conditions, others think that they are different presentations of the same disorder, ranging from a milder form (OTCS) to a more severe condition (BOS) [Bohring et al., 1999]. BOS is a rare malformation syndrome with only 30 cases described so far [Hastings et al., 2011]. It is characterized by exophthalmos, hypertelorism, severe intrauterine growth retardation, poor feeding, profound mental retardation, trigonocephaly, prominent metopic suture, nevus flammeus of the forehead, upslanting palpebral fissures, hirsutism, and flexion at the elbows, and wrists. The molecular basis of BOS and its inheritance are incompletely understood. It was associated with dominant mutations in the *ASXL1* gene (Additional Sex Combs-Like 1; MIM *612990). *ASXL1* gene maps to chromosome position 20q11.21 and it encodes the additional sex comb-like protein 1, which is a mammalian homolog of *Drosophila asx*. Recently, Hoischen et al. [2011] discovered that seven out of 13 BOS patients were heterozygotes for de novo mutations of this gene. Similar mutations in *ASXL1* were found in two BOS patients by Magini et al. [2012]. Although BOS is considered an autosomal dominant pathology due to de novo mutations in *ASXL1*, the case of two sibs diagnosed with BOS [Greenhalgh et al., 2003], suggests that this malformation syndrome could also display an autosomal recessive pattern of inheritance (although gonadal mosaicism should also be considered in this case, consistent with AD inheritance).

In this study, *CD96* and *ASXL1* were analyzed in 11 patients with OTCS or BOS.

MATERIALS AND METHODS

Patients and Samples

Most of the patients were diagnosed as OTCS or BOS by two of us (J.M.O., G.N.), and patients P9a and b, and P10 were diagnosed elsewhere (Fig. 1). Written informed consent was obtained from all patients' parents. We have obtained the consent to publish pictures of patients P5, P6, P7, P9a, P9b, P10a, and P10b.

Genomic DNA was obtained from the patients and parents from peripheral blood using Wizard[®] Genomic DNA Purification Kit (Promega, Madison, WI). Quantity and quality of the gDNA was assessed using a Nanodrop ND-1000 Spectrophotometer (NanoDrop Technologies Inc., Wilmington, DE).

Polymerase Chain Reaction (PCR) Amplification

Primers and PCR conditions for the amplification of the exons and flanking regions of *CD96* and *ASXL1* genes are summarized in Tables I and II, respectively. *ASXL1* sequence ENST00000375687 and *CD96* sequence ENSG00000153283 were taken as reference. Primers for *DSC2* amplification were: *DSC2_mut1_1-F*: TTA-GATCTTAATATTTGCCAGTG and *DSC2_mut1_1-R*: CATG-CAGTGTGTTGATTTTCTATT (Ta: 60°C); *DSC2_mut2_1-F*: TCTCCCCACGTGCATACATT and *DSC2_mut2_1-R*: CCATGT-GACACAGCCCTTTT (Ta: 62°C).

The PCR reactions were carried out with 0.2 μM of each dNTP, 0.4 μM of each primer and 0.7 u of GoTaq Flexy (Promega) in the presence of 50 ng of gDNA. All the reactions consisted of an initial denaturalization step of 4 min at 95°C; 35 cycles of 30 sec at 95°C, 30 sec at annealing temperature (T_a), and 5 sec at 72°C, followed by a final extension of 4 min at 72°C. For exon1 of the *ASXL1* gene, the GC-Rich PCR System (Roche, Basel, Switzerland) has been used. Briefly, 0.16 μM of each dNTP, 0.3 μM of each primer, 1 u of the GC-Rich Enzyme and 100 ng of gDNA. For the reactions, we performed an initial denaturalization step of 5 min at 95°C, 35 cycles of 30 sec at 95°C, 30 sec at 57°C, and 40 sec at 72°C, followed by a final extension of 5 min at 72°C.

The PCR products were purified with the MultiScreen[™] Vacuum Manifold 96-well plate (Merck Millipore, Bellerica, MA) following the manufacturer's instructions and quantified using NanoDrop ND-1000 Spectrophotometer (NanoDrop Technologies Inc.).

Sanger Sequencing

The sequencing reactions were performed using the BigDye[®] Terminator v3.1 Cycle Sequencing kit (Applied Biosystems, Foster City, CA). The samples were processed at the Scientific and Technological Centers (CCiT) of the University of Barcelona.

Whole Exome Sequencing

Exome capture and sequencing was performed at CNAG, Barcelona, Spain. Briefly, the exons were captured by Agilent SureSelect Human All Exon kit (Santa Clara, CA) and sequenced by Illumina HiSeq2000 (San Diego, CA).

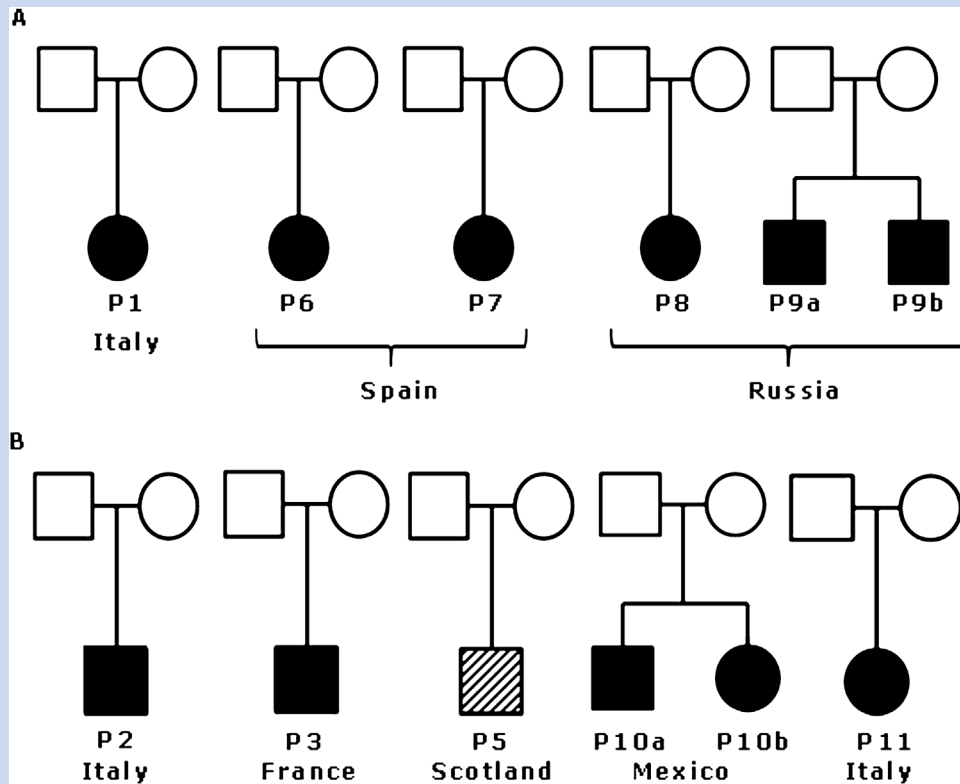


FIG. 1. Pedigrees of patients included in this study. A: Patients included in the exome-sequencing project. B: Patients analyzed by Sanger sequencing. OTCS patients are depicted in black while the only BOS patient is indicated by a dashed pattern.

Base calling and quality control were performed using the Illumina RTA sequence analysis pipeline. Analysis of the primary data (FASTQ files) was done using the BIErS platform pipeline (CIBERER), which was as follows. Sequence reads were aligned to the human reference genome build GRCh37 (hg19) using the Burrows-Wheeler Aligner (BWA) [Li and Durbin, 2009]. Mapped reads were filtered (leaving only those mapping in unique genomic positions with enough quality), sorted and indexed with SAMtools [Li et al., 2009]. GATK [McKenna et al., 2010] was then used to realign the reads as well as for the base quality score recalibration. Once a satisfactory alignment was achieved, identification of single nucleotide variants and Indels was performed using GATK standard hard filtering parameters [DePristo et al., 2011]. For the final exome sequencing analysis report we used the VARIANT [Medina et al., 2012] annotation tool, which provides additional relevant variant information for the final process of candidate gene selection. In particular, minor allele frequency (MAF), obtained from dbSNP [Sherry et al., 2001] and 1,000 Genomes project [Abecasis et al., 2012], was provided to help on the selection of new variants not reported in healthy populations to date. SIFT [Kumar et al., 2009] and Polyphen [Adzhubei et al., 2010] damage scores were computed to predict the putative impact of the discovered variants over the protein structure and functionality. This information was completed with the evolutionary conservation obtained from PhastCons [Siepel et al., 2005]. Also disease related annotations,

at both variant and gene levels were provided if available. Finally, GO terms for the affected genes were also retrieved. The successive application of quality control filters and the prioritization by the parameters accounting for potential functional impact led us to build up a list of candidate genes (and variants) ranked by its segregation with the cases and the putative potential impact. Such a prioritization list was further inspected to look for potential candidate genes and/or variants. Candidate variants were visualized by IGV software [Thorvaldsdottir et al., 2013].

RESULTS

Patients' Phenotypes

The available clinical findings of the patients are summarized in Table III and pictures of most of them are shown in Figure 2. Patient P1 was previously reported (and pictures included) in Lalatta et al. [1990].

Search for Mutations Within the *CD96* Coding Sequence

For the patients subjected to WES (Fig. 1A), the *CD96* genomic region was analyzed from the BAM files using the IGV software. All exons were properly captured and sequenced (with an average

TABLE I. Primers and PCR Conditions for *CD96* Coding Region Amplification

Primer name	Sequence 5'-3'	Exon	Size (bp)	T _a [°C]	[MgCl ₂] (mM)
CD96-1F	CCAGGCGTGTGTGGTAGAGT	1	277	62	1.5
CD96-1R	CCTGTGACTGCTGCTGAAA				
CD96-2F	TCTCATGCATCTCTATCTGAGTGA	2	685	62	1.5
CD96-2R	GACAGGAAGTGACCCACAGCA				
CD96-3F	CCCTGAGGACAGATGAATCC	3	365	62	1.5
CD96-3R	ATTATGCCAGTGGTGGGAAAG				
CD96-4F	AGGGGGTACCTGCCTTCTTA	4	427	62	2
CD96-4R	CATCCTCTGTTTCTGCCAT				
CD96-5F	TCAGAAGAACAGAATGCTTCCA	5	825	62	2.5
CD96-5R	GGGGACTCTCTGAAGAATC				
CD96-6F	AGGTAGGATGACATTTGGTGC	6	317	62	2
CD96-6R	CTCTCAGAATGTTGATGTGCA				
CD96-7F	GCCCATTATAGTGCACGTTCT	7	400	62	2
CD96-7R	TCCAAGAAAAACATCATTCTGC				
CD96-8F	ACCATGGATCAATGACATGC	8	568	62	2
CD96-8R	TTTGACAAGTAGGACTCCAGTGA				
CD96-9F	TGATGAATAAATAAAGGAAAAGTG	9	654	58	2.5
CD96-9R	CCAAAACAATGTTCTCAGTGG				
CD96-10F	GGCTGTTCACTAAGATTCTTTC	10–11	942	62	2.5
CD96-11R	TGAGACTACACCCATGGACAAA				
CD96-12F	TCCCACCTTTGTTGAGGACA	12	397	62	2
CD96-12R	GGAAACAAAATTCTTCTCAGCC				
CD96-13F	GGATCCCAGCCTTGCTATAA	13	663	58	2.5
CD96-13R	TGAGAAAGAAATCATTGGAACAAA				
CD96-14F	GAAAATTTCTGGTAGGGTACGTAAT	14	585	62	2
CD96-14R	GAGCAAGTCCGTGGACATG				
CD96-15F	TGCTGAAAGAAGTGGGAGAG	15	593	62	2
CD96-15R	TGGTTCAACTGTATGCCCA				

coverage of 76.2 ± 13.7). Low quality changes detected were verified by Sanger sequencing and were discarded because they were false positives. For the remaining five patients, the 15 coding exons and their flanking regions were Sanger sequenced. No mutation was found in any of the 11 patients included in this study.

Search for Mutations Within the *ASXL1* Coding Sequence

The genomic region of *ASXL1* was analyzed in silico by IGV in the six patients included in the exome project. The average coverage for the *ASXL1* gene in these samples was 34.6 ± 6.7 . Exons 1, 7, 8, and the 5' fragment of exon 13 (13.1) were poorly captured and, thus, were sequenced by the Sanger method in all the patients. In addition, the 13 exons and flanking regions were Sanger-sequenced in the patients not included in the exome project.

In patient P5's exon 13 we found a heterozygous 1 bp duplication (c.2100dupT, p.Pro701Serfs*16) absent in his parents. It was thus, a de novo mutation. No other mutation was found in the remaining patients.

Analysis of Genomic Region 18q12.1

For the patients subjected to WES, we analyzed by IGV a 3.22 Mb region between chr18:28495126 and chr18:31717104

that includes the desmocollin (*DSC*) and desmoglein (*DSG*) gene clusters. In particular, the exons of 20 genes within the region, including *ASXL3*, were analyzed (Table IV). For this region, we have an average coverage of 70.3 ± 35.7). The only changes found were two missense mutations in the *DSC2* gene (p.Glu46Lys and p.Glu102Lys) in a compound heterozygous state in patient P1. Mutation p.Glu46Lys (rs180908546; MAF: 0.0005 in 1000 Genomes and MAF: 0.00007 in ESP6500) was inherited from the patient's father while p.Glu102Lys (rs144799937; MAF: 0.00076 in ESP6500) was inherited from her mother.

DISCUSSION

Little is known of the molecular bases of the OTCS and BOS syndromes. To date, only one gene, *CD96*, has been associated with OTCS by Kaname et al. [2007], who reported an OTCS patient bearing a balanced chromosomal translocation, t(3;18)(q13.13; q12.1) that disrupted *CD96* at 3q13. The precise breakpoint was within *CD96* exon five and led to a premature termination of the protein. In that patient, *CD96* mRNA expression was reduced to 50%. Moreover, in the mutation analysis of nine karyotypically normal patients diagnosed with OTCS or BOS, Kaname et al. [2007] also identified a missense mutation (c.839C>T, p. Thr280Met) in one BOS patient, not found in controls. In our

TABLE II. Primers and PCR Conditions for ASXL1 Coding Region Amplification

Primer name	Sequence 5'-3'	Exon	Size (bp)	Ta [°C]	[MgCl ₂] (mM)
ASXL1-1F	GAGCCGTGACCTCTGACC	1	581	62	2
ASXL1-1R	GAGGGCGAGCGGAAAAAGG				
ASXL1-2F	GGTCTCGCATACTATACCATG	2	572	62	2.5
ASXL1-2R	GGAAGAACAAGGAGATGGGG				
ASXL1-3F	TGTGGGGAGGGGAAGATTGAG	3	445	62	2.5
ASXL1-3R	CCTTGAACACACTGGATGC				
ASXL1-4F	AGTGTAGTTATGGATTCGGG	4	475	62	2.5
ASXL1-4R	CATCAGTGTCACCTGACTGC				
ASXL1-5F	GGTCAGTTAGAAAGGGTTAGG	5–6	512	62	2.5
ASXL1-6R	GCTCACTACAGGAGAAGGAG				
ASXL1-7F	ATAGTGTGCGCCAGGGAATGC	7–8	860	62	2.5
ASXL1-8R	GACATCATCTTCTCACTAGGC				
ASXL1-9F	AGGAGATGCAACCCCAAGTG	9–10	674	62	2.5
ASXL1-10R	TAACCCCTTTGAGAAGAGCGAG				
ASXL1-11F	CTCTGTCCCTATAAGAGCATG	11	527	62	2.5
ASXL1-11R	ATCACAGCCATCAGTTTCAGG				
ASXL1-12F	CCATTATAGTGAAGCTAACAG	12	875	62	2.5
ASXL1-12R	GAGTTAAGGGCTCTATAATCTC				
ASXL1-13.1F	TGATTCTGTATGCCATGACCC	13.1	797	62	2.5
ASXL1-13.1R	TGCTCCTCATCATCACTTTCC				
ASXL1-13.2F	CTACTGTCTCCCAAACCTC	13.2	868	62	2.5
ASXL1-13.2R	CCAGACGCATGTACCATTTC				
ASXL1-13.3F	TACAGCCTCTGACTTTGAAGG	13.3	935	62	2.5
ASXL1-13.3R	CAGCCACATCCCAGAGCC				
ASXL1-13.4F	GAACACCTCGTTTCTCATCTC	13.4	946	62	2.5
ASXL1-13.4R	TGGGGGAAGGCAAGAGTGC				

study, we did not find any *CD96* mutation in the 11 patients included in the present study.

The relationship between *CD96* and Opitz C syndrome was questioned recently as this gene was found disrupted in patients with renal cell carcinoma without any resemblance to Opitz C patients [Darlow et al., 2013]. Alternatively, it was proposed that in Kaname's patient, the breakpoint region on chromosome 18 (18q12.1) may be the one bearing the OTCS causative mutation. This region is now known to comprise the desmocollin and desmoglein gene clusters, responsible for tight junction formation in epithelia. Additionally, it includes the *ASXL3* gene (a paralog of *ASXL1*), which was recently associated with a syndrome with phenotypical overlap with BOS [Bainbridge et al., 2013]. It should be very interesting to sequence this gene in a sample from the patient with the t(3;18) translocation described by Kaname et al. [2007].

In our study, we scrutinized the exon sequences within 3.22 Mb of chromosome region 18q12.1 of the six patients subjected to WES. In patient P1 (OTCS) we found two mutations in the *DSC2* gene (p.Glu46Lys and p.Glu102Lys). Both mutations are present in the general population albeit with a low frequency (MAFs <0.001) and both are classified as benign in Polyphen2 (with scores of 0.006 and 0.016, respectively). The p.Glu102Lys mutation was reported previously in a heterozygous state in a patient with arrhythmogenic right ventricular cardiomyopathy (ARVC) [Anastasakis et al., 2012]. The clinical manifestations of patient P1 were previously

reported by Lalatta et al. [1990] (as patient 3; C.L.), and at age 4 years, this patient did not present any kind of cardiomyopathy. However, ARVC is usually manifest in late adulthood. Interestingly, Andreassen et al. [2013] have pointed out that a large number of the mutations reported as associated with a cardiomyopathy are not, in fact, the monogenic cause of the disease. Many of these changes (14–18%), including the p.Glu102Lys mutation, are found in public databases such as the NHLBI Exome Sequencing Project (ESP). According to the observed frequency of these mutations in ESP, the expected frequency of ARVC should be 1:5, a prevalence far higher than that observed in the general population, which is estimated as 1:5000. Also, when compared to the ones not present in the public databases, the mutations found in ESP differ significantly in the number of nonsense mutations (lower) and in the PolyPhen2 prediction (often classified as “benign”). All things considered, we understand that the *DSC2* mutations found in patient P1 are not responsible of her OTCS phenotype. No other putative pathogenic mutation was found in any of the remaining exons of the genes in the 18q12.1 region in the remaining patients included in the exome project. This includes *ASXL3*, a very interesting candidate. However, the exome analysis does not allow for the inspection of regulatory sequences located outside the exons.

In our study we have assessed the *ASXL1* gene, both in OTCS and BOS patients, and we have found a loss-of-function mutation in one patient with a clear diagnosis of BOS (P5). This mutation

TABLE III. Clinical Features

	P1	P2	P3	P5	P6	P7	P8	P9a	P9b	P10a	P10b	P11
Age at diagnosis (y)	4	14	NA	2	2	2	4	0.5	0	1	0	6
Consanguinity	No	No	NA	NA	No	No	No	No	No	No	No	No
MANIFESTATIONS CNS												
Developmental retardation	+	+	+	+	+	+	+	Very mild	No	+	+	+
Motor developmental delay								+	+			
Seizures				+	+	+	+					
Brain MRI				(1)		(2)	(3)	(4)	Normal			(5)
HEAD												
Trigonocephaly	+	+	+	+	+	+	(6)	+	+	+	+	+
Facial anomalies	+	+	+	+		+	+	+	+	+	+	+
Myopia				+						+	NA	
Strabismus	+	+	+							+	NA	
Low-set and abnormally shaped ears	+			+	+		+			+	+	+
Forehead hemangioma										+	+	
Cutis marmorata/livedo reticularis							+					+
NECK												
Short, webbed neck			+		+					+	+	
THORAX												
Widely spaced nipples	+										+	
Scoliosis						Mild		Severe	Severe			Severe
LIMBS												
Short limbs	+											
Flexion deformities	+				+	+		+	+			
Brachydactyly	+									+		
Single palmar crease	+							+	+			
Ulnar deviation of the fingers	+				+			+				
OTHER												
Generalized muscular atrophy	+							+	+			
Muscular hypotrophy												+
Hypotonia				+	+	+	+	+	+	+	+	+
Cryptorchidism		Bilateral	Bilateral					Left	Bilateral			
Horseshoe kidneys		+										
Failure to thrive				+	+					+		

NA, not available. [1] Posterior thinning corpus callosum noted on MRI; [2] Mild enlargement of the supratentorial ventricular system, mainly in the frontal horns, and asymmetric lateral ventricles. Mild elevation of the choline in the spectroscopy. [3] A brain MRI showed moderate distension of the bodies and back horns of tricornes and of parieto-occipital subarachnoid spaces; [4] MRI CNS: Dimorphic ventriculomegaly with thin corpus callosum and white matter gliosis; [5] Brain MRI showed peritrigonal white matter thinner and mild ventricular enlargement; [6] mild brachycephaly, prominence of the metopic suture without definite trigonocephaly.

(c.2100dupT, p.Pro701Serfs*16) consists of an insertion of a T at position 2100 of the cDNA, leading to a change in the amino acid at residue 701 and a premature truncation of the protein. This change was found in patient P5 but was absent in his parents, being a de novo change. This mutation is located in exon 13, as all but one (p.Arg404X) of the *ASXL1* mutations previously associated with BOS [Hoischen et al., 2011; Magini et al., 2012]. And, as all of them, it leads to a premature end of the protein. All these facts suggest that this mutation is the cause of the BOS phenotype in the P5 patient.

In summary, we have not found any mutation in the *CD96* gene or in the 18q12.1 region that could explain the OTCS or BOS

phenotypes of our patients. In contrast, we have found a de novo mutation in the *ASXL1* gene in the BOS patient, adding a novel mutation to those described for BOS and found no *ASXL1* mutation in OTCS patients. Phenotypically, it is hard to define salient features allowing a clear distinction between these two conditions, except perhaps for the severity, which tends to be more marked in the BOS. The genes might provide a better distinction. For example, *ASXL1* mutations were found only in BOS. But half of the BOS patients remain undiagnosed at the molecular level. However, it may happen that as soon as there is a new gene for OTCS, a patient with mutation in this gene will be considered BOS by some

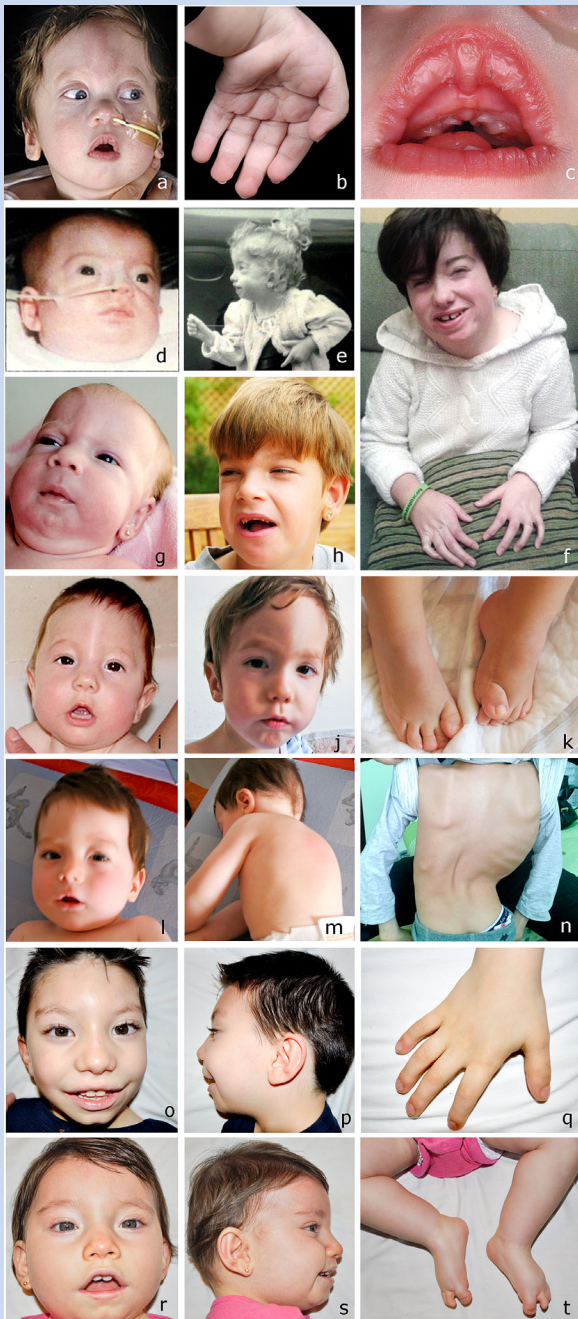

FIG. 2. Clinical presentation of the patients. Patient P5 at 2y (a–c). Note the capillary naevus on forehead, trigonocephaly and ulnar deviation of the hand. Patient P6 at 1 year (d), 4 years (e), and 18 years (f). Patient P7 at 1 month (g) and 8 years of age (h). Frontal facial view of Patient P9a at 10 months (i) and 2 years (j). Note metopic suture ridging, myopathic facies with open mouth and overlapping toe of the foot (k). Frontal facial view (l) and back (m) of P9b at 2 months. Notice the severe scoliosis and its progression at 4 years (n). Patient P10a at 4 years (o–q). Notice the short fingers (q). Patient P10b at 14 months (r–t). Both P10 sibs presented with trigonocephaly, hypoplastic orbital ridges and prominent eyes. [Color figure can be seen in the online version of this article, available at <http://wileyonlinelibrary.com/journal/ajmga>]

TABLE IV. Genes Analyzed in the 18q12.1 Region

<i>DSC2</i>	<i>DSG2</i>	<i>TRAPPC8</i>	<i>WBP11P</i>
<i>DSC1</i>	<i>TTR</i>	<i>RNF125</i>	<i>KLHL14</i>
<i>DSG1</i>	<i>B4GALT6</i>	<i>RNF138</i>	<i>C18orf34</i>
<i>DSG4</i>	<i>SLC25A52</i>	<i>MEP1B</i>	<i>ASXL3</i>
<i>DSG3</i>	<i>MCART2</i>	<i>FAM59A</i>	<i>NOL4</i>

clinicians. Further analysis of the exome sequencing, in a hypothesis-free approach, currently underway, should help shed light on the molecular bases of OCTS.

ACKNOWLEDGMENTS

The authors thank the patients and their families for their whole-hearted collaboration and Dr. Karen Naismith, Dr. María del Carmen Esmer, Dr. Francina Munell, and Dr. María Amparo Alonso for sharing clinical information of specific patients. They are also grateful for the technical assistance of Ms. M. Cozar. Funding was from Associació Síndrome Opitz C, Terrassa, Spain; Spanish Ministerio de Ciencia e Innovación (SAF2011-25431; SAF2014-56562-R; FECYT, crowdfunding PRECIPITA); Catalan Government (2009SGR971, 2014SGR932), and from CIBERER (U720).

REFERENCES

- Abecasis GR, Auton A, Brooks LD, DePristo MA, Durbin RM, Handsaker RE, Kang HM, Marth GT, McVean GA. 2012. An integrated map of genetic variation from 1,092 human genomes. *Nature* 491:56–65.
- Adzhubei IA, Schmidt S, Peshkin L, Ramensky VE, Gerasimova A, Bork P, Kondrashov AS, Sunyaev SR. 2010. A method and server for predicting damaging missense mutations. *Nat Methods* 7:248–249.
- Anastasakis A, Vouliotis AI, Protonotarios N, Stefanadis C. 2012. Arrhythmogenic right ventricular cardiomyopathy: The challenge of genetic interpretation in clinically suspected cases. *Cardiology* 123:190–194.
- Andreasen C, Nielsen JB, Refsgaard L, Holst AG, Christensen AH, Andreasen L, Sajadieh A, Haunso S, Svendsen JH, Olesen MS. 2013. New population-based exome data are questioning the pathogenicity of previously cardiomyopathy-associated genetic variants. *Eur J Hum Genet* 21:918–928.
- Antley RM, Hwang DS, Theopold W, Gorlin RJ, Steeper T, Pitt D, Danks DM, McPherson E, Bartels H, Wiedemann HR, Opitz JM. 1981. Further delineation of the C (trigonocephaly) syndrome. *Am J Med Genet* 9:147–163.
- Bainbridge MN, Hu H, Muzny DM, Musante L, Lupski JR, Graham BH, Chen W, Gripp KW, Jenny K, Wienker TF, Yang Y, Sutton VR, Gibbs RA, Ropers HH. 2013. De novo truncating mutations in *ASXL3* are associated with a novel clinical phenotype with similarities to Bohring-Opitz syndrome. *Genome Med* 5:11.
- Bohring A, Silengo M, Lerone M, Superneau DW, Spaich C, Braddock SR, Poss A, Opitz JM. 1999. Severe end of Opitz trigonocephaly (C) syndrome or new syndrome? *Am J Med Genet* 85:438–446.
- Darlow JM, McKay L, Dobson MG, Barton DE, Winship I. 2013. On the origins of renal cell carcinoma, vesicoureteric reflux and C (Opitz

- trigonocephaly) syndrome: A complex puzzle revealed by the sequencing of an inherited t(2;3) translocation. *Eur J Hum Genet* 21:145.
- DePristo MA, Banks E, Poplin R, Garimella KV, Maguire JR, Hartl C, Philippakis AA, del Angel G, Rivas MA, Hanna M, McKenna A, Fennell TJ, Kernysky AM, Sivachenko AY, Cibulskis K, Gabriel SB, Altshuler D, Daly MJ. 2011. A framework for variation discovery and genotyping using next-generation DNA sequencing data. *Nat Genet* 43:491–498.
- Fuchs A, Cella M, Giuriso E, Shaw AS, Colonna M. 2004. Cutting edge: CD96 (tactile) promotes NK cell-target cell adhesion by interacting with the poliovirus receptor (CD155). *J Immunol* 172:3994–3998.
- Greenhalgh KL, Newbury-Ecob RA, Lunt PW, Dolling CL, Hargreaves H, Smithson SF. 2003. Siblings with Bohring-Opitz syndrome. *Clin Dysmorphol* 12:15–19.
- Hastings R, Cobben JM, Gillessen-Kaesbach G, Goodship J, Hove H, Kjaergaard S, Kemp H, Kingston H, Lunt P, Mansour S, McGowan R, Metcalfe K, Murdoch-Davis C, Ray M, Rio M, Smithson S, Tolmie J, Turnpenny P, van Bon B, Wiczorek D, Newbury-Ecob R. 2011. Bohring-Opitz (Oberklaid-Danks) syndrome: Clinical study, review of the literature, and discussion of possible pathogenesis. *Eur J Hum Genet* 19:513–519.
- Hoischen A, van Bon BW, Rodriguez-Santiago B, Gilissen C, Vissers LE, de Vries P, Janssen I, van Lier B, Hastings R, Smithson SF, Newbury-Ecob R, Kjaergaard S, Goodship J, McGowan R, Bartholdi D, Rauch A, Peippo M, Cobben JM, Wiczorek D, Gillessen-Kaesbach G, Veltman JA, Brunner HG, de Vries BB. 2011. De novo nonsense mutations in *ASXL1* cause Bohring-Opitz syndrome. *Nat Genet* 43:729–731.
- Kaname T, Yanagi K, Chinen Y, Makita Y, Okamoto N, Maehara H, Owan I, Kanaya F, Kubota Y, Oike Y, Yamamoto T, Kurosawa K, Fukushima Y, Bohring A, Opitz JM, Yoshiura K, Niikawa N, Naritomi K. 2007. Mutations in *CD96*, a member of the immunoglobulin superfamily, cause a form of the C (Opitz trigonocephaly) syndrome. *Am J Hum Genet* 81:835–841.
- Kumar P, Henikoff S, Ng PC. 2009. Predicting the effects of coding non-synonymous variants on protein function using the SIFT algorithm. *Nat Protoc* 4:1073–1081.
- Lalatta F, Clerici Bagozzi D, Salmoiraghi MG, Tagliabue P, Tischer C, Zollino M, Di Rocco C, Neri G, Opitz JM. 1990. “C” trigonocephaly syndrome: Clinical variability and possibility of surgical treatment. *Am J Med Genet* 37:451–456.
- Li H, Durbin R. 2009. Fast and accurate short read alignment with Burrows-Wheeler transform. *Bioinformatics* 25:1754–1760.
- Li H, Handsaker B, Wysoker A, Fennell T, Ruan J, Homer N, Marth G, Abecasis G, Durbin R. 2009. The sequence alignment/map format and SAMtools. *Bioinformatics* 25:2078–2079.
- Magini P, Della Monica M, Uzielli ML, Mongelli P, Scarselli G, Gambineri E, Scarano G, Seri M. 2012. Two novel patients with Bohring-Opitz syndrome caused by de novo *ASXL1* mutations. *Am J Med Genet A* 158A:917–921.
- McKenna A, Hanna M, Banks E, Sivachenko A, Cibulskis K, Kernysky A, Garimella K, Altshuler D, Gabriel S, Daly M, DePristo MA. 2010. The genome analysis Toolkit: A MapReduce framework for analyzing next-generation DNA sequencing data. *Genome Res* 20:1297–1303.
- Medina I, De Maria A, Bleda M, Salavert F, Alonso R, Gonzalez CY, Dopazo J. 2012. VARIANT: Command line, web service and web interface for fast and accurate functional characterization of variants found by next-generation sequencing. *Nucleic Acids Res* 40:W54–W58.
- Opitz JM, Putnam AR, Comstock JM, Chin S, Byrne JL, Kennedy A, Frikke MJ, Bernard C, Albrecht S, Der Kaloustian V, Szakacs JG. 2006. Mortality and pathological findings in C (Opitz trigonocephaly) syndrome. *Fetal Pediatr Pathol* 25:211–231.
- Sargent C, Burn J, Baraitser M, Pembrey ME. 1985. Trigonocephaly and the Opitz C syndrome. *J Med Genet* 22:39–45.
- Sherry ST, Ward MH, Kholodov M, Baker J, Phan L, Smigielski EM, Sirotkin K. 2001. dbSNP: The NCBI database of genetic variation. *Nucleic Acids Res* 29:308–311.
- Siepel A, Bejerano G, Pedersen JS, Hinrichs AS, Hou M, Rosenbloom K, Clawson H, Spieth J, Hillier LW, Richards S, Weinstock GM, Wilson RK, Gibbs RA, Kent WJ, Miller W, Haussler D. 2005. Evolutionarily conserved elements in vertebrate, insect, worm, and yeast genomes. *Genome Res* 15:1034–1050.
- Thorvaldsdottir H, Robinson JT, Mesirov JP. 2013. Integrative Genomics Viewer (IGV): high-performance genomics data visualization and exploration. *Brief Bioinform* 14:178–192.